

THE PRESENCE OF THE HYALURONAN RECEPTOR CD44 IN THE  
REPRODUCTIVE TRACT OF THE MARE

Except where reference is made to the work of others, the work described in this thesis is my own or was done in collaboration with my advisory committee. This thesis does not include proprietary or classified information.

---

Isabel Rodriguez Hurtado

Certificate of Approval:

---

Elizabeth Whitley  
Assistant Professor  
Pathobiology

---

Allison Stewart, Chair  
Assistant Professor  
Clinical Sciences

---

Fred Caldwell  
Assistant Professor  
Clinical Sciences

---

Dwight Wolfe  
Professor  
Clinical Sciences

---

George T. Flowers  
Interim Dean  
Graduate School

THE PRESENCE OF THE HYALURONAN RECEPTOR CD44 IN THE  
REPRODUCTIVE TRACT OF THE MARE

Isabel Rodriguez Hurtado

A Thesis

Submitted to

the Graduate Faculty of

Auburn University

in Partial Fulfillment of the

Requirements for the

Degree of

Master of Science

Auburn, Alabama  
December 17, 2007

THE PRESENCE OF THE HYALURONAN RECEPTOR CD44 IN THE  
REPRODUCTIVE TRACT OF THE MARE

Isabel Rodriguez Hurtado

Permission is granted to Auburn University to make copies of this thesis at its  
discretion, upon request of individuals or institution at their expense.  
The author reserves all publications rights.

---

Signature of Author

---

Date of Graduation

THESIS ABSTRACT

THE PRESENCE OF THE HYALURONAN RECEPTOR CD44 IN THE  
REPRODUCTIVE TRACT OF THE MARE

Isabel Rodriguez Hurtado

Master of Sciences, December 17, 2007  
(LMV, Universidad Complutense de Madrid, 2001)

61 Typed Pages

Directed by Allison Stewart

Objective - To investigate the presence and localization of the hyaluronan receptor CD44 in the reproductive tract of the mare.

Animals – Six adult mares

Procedures - Tissue sections of ovaries, oviducts and uterus were obtained from healthy mares. Positive control samples were obtained from the same mares and were processed together with the reproductive tissues. These control tissues included synovium and lymph node. The samples were fixed in 10% buffered neutral formalin or glutaraldehyde/formalin. Formalin samples were stained with hematoxylin-eosin to rule out pathologic changes or processed for immunohistochemical analysis. The later samples were stained with a primary monoclonal antibody against CD44 (Rat anti-CD44s monoclonal) and a secondary rabbit, anti-rat antibody (Biotinylated Rabbit anti-Rat). The

slides were evaluated under light microscopy for binding of specific antibody. Results were described according to stain identification, location, percentage of stained cells (CD44-reactive cells per 100 cells of one histological stratus). Samples fixed with glutaraldehyde/formalin were stained with the primary antibody Rat anti-CD44s monoclonal and gold conjugated protein A. These samples were evaluated using a transmission electron microscope for localization of gold particles.

Results – Positive immunolabelling for CD44 was found in all the tissues evaluated. CD44 was localized in the uterine endometrium but not in the uterine glands. Positive immunolabelling was found all throughout the epithelial cells in all tubal segments evaluated. This stain was confined to the ad-luminal surface and supra-nuclear regions. The areas of higher uptake were found on the basal surface of the tubular epithelial cells. Both inner and outer portions of the ovaries had cell that were populations positive for CD44. Serosal epithelia were intermittently positive.

Conclusions and Clinical Relevance – This is the first time CD44 has been identified in the reproductive tract of the mare. The localization of CD44 in the ovaries, oviducts and endometrium, suggest a role of CD44-HA in fertilization and embryonic implantation in the mare.

## ACKNOWLEDGMENTS

The author will like to thank Dr. Allison Stewart for providing me with exceptional clinical and personal guidance, Dr. Elizabeth Whitley for her invaluable assistance and knowledge during this project, Drs. Fred Caldwell, Earl Gaughan and Marybeth Stanton for their mentorship throughout my residency and Master programs, and Maria Torivio-Kinnucan for her technical support and time devoted to this project. I will like to express my special gratitude to Dr. Dwight Wolfe for his care and unconditional support throughout my residency and this project.

I would also like to thank the Birmingham Racing Commission for providing the funds to complete the project.

Style manual or journal used: Journal of Theriogenology

Computer software used: Microsoft Office Word 2003

## TABLE OF CONTENTS

LIST OF FIGURES.....	x
LIST OF TABLES.....	xi
INTRODUCTION.....	1
REVIEW OF LITERATURE.....	4
Adhesion molecules.....	4
Hyaluronan.....	4
CD44.....	5
CD44, HA and Inflammation.....	7
Synovial physiology and CD44.....	9
Lymph node physiology and CD44.....	10
Roles of CD44 in reproductive physiology.....	10
Roles of CD44 in reproductive pathology.....	11
Technical considerations.....	12
Immunohistochemistry.....	13
Immunoelectron Microscopy.....	14
OBJECTIVES.....	15
MATERIALS AND METHODS.....	16
Animals.....	17



Sample collection.....	17
Experimental methods .....	18
RESULTS.....	21
Immunohistochemistry.....	21
Immunoelectron microscopy.....	23
DISCUSSION.....	25
REFERENCES.....	30

## LIST OF FIGURES

Fig. 1(a, b and c): Immunolabelling for CD44 in the equine oviduct.....	41
Fig. 2(a-c): Immunolabeling for CD44 in the equine uterus.....	44
Fig. 3 (a-c): Electron microscopy for CD44 in the equine infundibulum .....	48

## LIST OF TABLES

Table 1- Signalment of the mares used in the study. ....	49
Table 2- Expression of CD44 by segments of the mare reproductive tracts . ....	50

## INTRODUCTION

Hyaluronan (HA) is a high molecular weight glycosaminoglycan (GAG) present in interstitial spaces and on basal membranes of proliferating epithelia, including the reproductive tract.(1) Hyaluronan is involved in fundamental events in the female reproductive tract of many mammalian species, including oocyte maturation, sperm storage, fertilization, and embryo implantation and development.(2) These functions are most likely mediated by its major cell surface receptor, CD44. To date, the function of the CD44-HA system has not been investigated in reproductive tissues in mares.

The CD44 molecule is a complex family of adhesion molecules widely distributed on epithelial cells, fibroblasts, granulocytes, lymphocytes, erythrocytes, hepatocytes, endothelial cells and synoviocytes.(3) As a cell-surface glycoprotein, CD44 is involved in cell-to-cell and cell-to-matrix interactions, signal transduction, lymphocyte adhesion and uptake, and degradation of HA.(4-7) CD44 has an extracellular domain with two binding sites; one has affinity for endothelial venules, and the other for HA.(5)

The CD44 molecule and its ligand, HA, have been implicated in inflammatory processes. The CD44-HA system plays a role in mediation of leukocyte rolling and extravasation, localization of cells within inflamed tissues, induction of inflammatory gene expression in leukocytes and parenchymal cells, and matrix remodeling.(8) Several lines of evidence link CD44 with fibroblast adhesion, migration and the development of fibrosis.(9-12) Fibrosis is a result of the invasion of a provisional fibrin matrix,

in a wounded tissue, by myofibroblasts. The matrix receptor CD44 is expressed on the surface of fibroblasts and mediates the fibrotic response after tissue injury. The HA binding site of CD44 also binds to chondroitin sulfate and matrical proteins like fibronectin, laminin, and collagen,(5,13) which may induce the formation of fibrous tissue, resulting in the development of post-surgical adhesions between viscera or transluminal adhesions in tubular organs. Dilute aqueous solutions of HA and HA gels can provide a protective tissue coating and have been associated with the prevention of adhesion formation in human and equine patients.(14-17) Hyaluronan has potential as a prophylactic agent against adhesions by the interaction of HA with the CD44 receptor. (14,18,19)

Various isoforms of CD44 have been identified in reproductive tissues of humans and of laboratory and domestic animal species. Functions of CD44 in these tissues include maintenance of the integrity of the epithelial sheet, modulation of cell invasion and migratory capacities during menstrual re-epithelization in primates, prevention of granulosa cell apoptosis, oocyte development and embryo implantation.(10,13,20-23) The CD44-HA system is implicated in reproductive pathologies such as the progression and metastasis of ovarian tumors and endometrial carcinomas in women.(24-27) Reproductive tract neoplasias are uncommon in mares, although chronic, degenerative pathologies and serosal or ovarian adhesions are major causes of infertility and may be related to the CD44-HA interaction.(28-31).

The present study was conducted to investigate the presence and localization of the CD44 receptor in the reproductive tract of the mare. For this purpose, tissue sections

of ovaries, oviducts, and uterus from healthy mares were evaluated with immunohistochemical and immunoelectron microscopy methods.

## **REVIEW OF LITERATURE**

### **Adhesion Molecules**

Cell adhesion mechanisms are essential to important processes like migration of inflammatory cells, epithelial construction and repair, and implantation of the embryo. Adhesion molecules such as integrins, cadherins, and CD44 are not only involved in embryonic implantation, but also function in anchorage and migration of neoplastic cells.(32,33)

The endometrium responds to ovarian steroids by undergoing a series of changes preparing for embryonic implantation. Alteration of the endometrial surface includes the expression of cell surface molecules, especially adhesion molecules. Mucins are downregulated during the receptive phase of the endometrium as they impair embryo interaction with the epithelial layer.(34) Integrins and cadherins, on the other hand, are believed to be upregulated by the blastocysts during implantation. In rabbits, CD44 is expressed most strongly in the luminal uterine epithelium during the pre-implantation phase, but in human beings, CD44 is expressed during both the menstrual cycle and pregnancy.

### **Hyaluronan**

Hyaluronan is a high molecular weight glycosaminoglycan (GAG) composed of the disaccharides D-glucuronic acid and N-acetyl-D-glucosamine. It is synthesized by a multi-isoform family of glycosyltransferases termed the HA synthases.(35) Hyaluronan

is regarded as an extracellular matrix component that promotes cell locomotion and proliferation.(36) In hyaluronan rich tissues, the hyaluronan filaments establish a matrix with aggregating proteoglycans and stabilizing molecules such as link protein and inter-alpha trypsin inhibitor.(36) This pericellular matrix is important for the stabilization and locomotion of cells detaching during mitotic cell rounding. Hyaluronan is present in the interstitial spaces and on the basal membranes of proliferating epithelia, including the reproductive tract.(1) The following properties have been related to HA: analgesic, anti-inflammatory, cartilage matrix protection, and prevention of adhesion formation. (16,18,37) The multiple biological functions of HA are mediated by its major surface receptor, CD44.

### **The CD44 Adhesion Molecule**

The CD44 group is a complex family of adhesion molecules produced from one gene by splicing and translational modification.(7,38) The CD44 gene consists of 20 exons, 10 of which are normally expressed, encoding for the standard form of CD44. The additional 10 exons are expressed by alternative splicing of the nuclear RNA that encode for extracellular regions. The resulting group of CD44 glycoproteins contains isoforms that differ both in amino acid sequence and carbohydrate composition. (7)

The regulation of CD44 isoforms and their activities is currently under investigation,(39) Regulation is believed to be related to hyaluronan binding, variations of the cytoplasmic and transmembrane domains, alternative splicing, and glycosylation.(7) CD44 isoforms are expressed as trans-membrane proteins under many



circumstances and are found in adult and fetal life, in normal and malignant cells, and in the immune system and other tissues.(34)

The HA receptor, CD44, is widely distributed on epithelial cells, fibroblasts, granulocytes, lymphocytes, erythrocytes, hepatocytes, endothelial cells, and synoviocytes.(3) As a cell-surface glycoprotein, CD44 is involved in cell-to-cell and cell-to-matrix interactions, signal transduction, lymphocyte adhesion and uptake and degradation of HA.(4-7) The CD44 receptor has also been related to morphogenesis, tumor progression, inhibition of apoptosis and adhesion formation.(7,40-42)

The CD44 molecule has a large extracellular domain with two binding sites; one has affinity for endothelial venules, and the other for HA.(5) All isoforms of CD44 have the HA-binding domain located in the N-terminal region.(20,21) The HA binding site of CD44 also shows affinity for other matrix components like fibronectin, laminin, collagen and osteopontin,(10,13,22,23) as well as growth factors and cytokines.(43)

Hyaluronan is turned over both systemically, by the lymphatic system, and locally at the sites of production. The CD44 molecule participates in the uptake and degradation of HA.(44) The CD44 molecule does not have hyaluronidase activity itself, but assists in the uptake of HA into cells like pulmonary macrophages and chondrocytes, where it can be degraded in the lysosomes.(6,44)

### **The role of CD44 and HA in Inflammation**

The CD44 molecule and its ligand, hyaluronan, have been implicated in several inflammatory diseases.(8) The CD44 receptor activity is up-regulated during

inflammation such that it binds HA with higher affinity. The CD44 receptor can be induced to bind HA in cells activated with inflammatory stimuli, including cytokines.(39)

There are many proposed mechanisms for the promotion of inflammation by the interaction of CD44 and HA. Examples include mediation of leukocyte rolling and extravasation, localization of cells within inflamed tissues, induction of inflammatory gene expression in leukocytes and parenchymal cells, and in matrix remodeling.(8)

The CD44 molecule may be involved in regulating the clearance of apoptotic cells. This theory implicates CD44 in chronic inflammation.(8) Resolution of an inflammatory response depends on the elimination of infiltrating leukocytes and the clearance of apoptotic cells by phagocytic macrophages. Studies in mice with targeted deletions of several exons of the CD44 gene showed an association with an increase in apoptotic infiltrating cells.(8) Signaling by CD44 may regulate cell survival and clearance of apoptotic leukocytes during the evolution of an inflammatory response.(8)

Several lines of evidence link CD44 with fibroblast adhesion, migration, and the development of fibrosis. The HA binding site of CD44 also allows for binding to chondroitin sulfate and matrical proteins like fibronectin, laminin and collagen which are integral in the formation of adhesions.(10) Hyaluronan, fibronectin, and fibrin support cell motility and are present in tissues after acute injury, as with acute alveolar fibrosis, where CD44 can be detected in newly formed fibrotic tissue and at the leading edge of migrating fibroblasts. Anti-CD44 antibodies can inhibit fibroblast invasion of a fibrin matrix, suggesting that interruption of the CD44 function may attenuate or arrest the fibrotic response.(9)

Hyaluronan has the potential to function as a prophylactic agent against the formation of adhesions. Derivatives of HA prevent surgical adhesions by minimizing the formation of a fibrin matrix between serosal and synovial surfaces.(18) This effect is mediated by the interaction of formulations of HA with the CD44 receptor.(10) The fibrinolytic system is the principal modulator of adhesion formation, controlling the balance between fibrin deposition and degradation.(45) The lysis of fibrin into fibrin degradation products is achieved through the action of plasmin. Plasmin is converted from plasminogen by tissue plasminogen activator (tPA).(45) Sodium hyaluronate solutions may modulate adhesion formation by increasing tissue plasminogen activator (tPA) concentrations at the visceral peritoneal surface and enhancing mesothelial fibrinolysis.(46) Hyaluronan has also demonstrated anti-inflammatory effects, modulating chemotaxis and decreasing the formation and release of prostaglandins.(47)

### **Synovial physiology and CD44**

Hyaluronan is a major component of synovial fluid and of the extracellular matrix of cartilage, and is essential for normal synovial physiology.(48) The hyaluronan receptor, CD44, has been considered to play a role as a cell-to-cell and cell-to-extracellular matrix anchor during inflammatory processes of the synovial structures in human beings.(49,50) The localization of CD44 in synovial membranes has been described in healthy and pathologic samples of human beings(50), rats,(51), and horses.(52) Therefore, synovial membrane was chosen as one of the positive control tissues for immunohistochemistry (IHC) in this study.

The synovial membrane is composed of two different layers: an intima and a lamina propria. The intima is an incomplete layer, with a thickness of only one to four synoviocytes that are loosely arranged on a matrix of hyaluronan.(53) The intima has no basement membrane, allowing efflux of capillary exudates into the synovial cavity through gaps between synoviocytes. Synovial fluid is an ultrafiltrate of plasma. The lamina propria contains blood vessels, lymphatic vessels and nerves that are embedded in adipose, fibrous (dense collagen) or areolar (loose collagen) tissue. The surface of the synovium is projected into the joint cavity in the form of folds and small villi.(54)

Synoviocytes are mesenchymal in origin and are divided into two distinct types: type A synoviocytes (considered macrophages), type B or fibroblast-like synoviocytes.(54) Type C synoviocytes represent a transitional form between type A and B synoviocytes.(55) Type A synoviocytes act as resident macrophages and are derived from blood-borne mononuclear cells.(56) Type B synoviocytes produce matrix constituents like hyaluronan, collagens and fibronectin.(57) The CD44 molecule is expressed by normal fibroblast-like type B synovial cells, where it is believed to serve as an adhesion molecule among the type B cells to maintain the epithelial-like arrangement.(51)

### **Lymph node physiology and CD44**

One of the earliest functions proposed for CD44 was in the control of lymphocyte homing.(58) Studies using murine endothelial cell lines that express HA and CD44-positive lymphoid cells showed that the CD44-HA interaction was important in lymphocyte rolling, a prelude to the movement of leukocytes across endothelial

barriers.(59) The CD44 receptor is involved in leukocyte migration and activation.. (5,7,8) The up-regulation of CD44 in lymph nodes has been used as a prognostic marker for several neoplastic diseases in human beings.(33,42,60)

### **Roles of CD44 in reproductive physiology**

The hyaluronan-CD44 signaling pathway may have a role in epithelization, gamete production, fertilization and embryo development. Various isoforms of CD44 have been identified in human tissues, including cervical epithelium,(61) in epithelial and stromal cells of the endometrium,(62) follicular fluid (63) and ovarian tissue.(42) CD44 has also been identified in placental structures, oocytes, early embryos, and spermatozoa.(32,64-66)

Functions of CD44 in reproductive organs are considered to include: maintenance of the integrity of the epithelial sheet, modulation of cell invasion and migratory capacities during menstrual re-epithelization, prevention of granulosa cell apoptosis, oocyte development, and embryo implantation. (10,13,20-23)

The different functional sections of porcine and bovine oviduct have varying levels of expression of CD44.(2,67,68) In these animal species, CD44 is present in multiple stages of oocyte and embryo development, and is also involved in sperm storage and fertilization.(69,70) Also, CD44 has been detected in bull spermatozoa(71), but has not been described in other male reproductive tissues in domestic species. The concentration of GAGs, including HA, has been studied in the bovine reproductive tract.(72) and were described in follicular, oviductal and uterine fluids of mares where GAGs were related to fertilization. The quantity and concentrations of

glycosaminoglycans, including HA, were increased in the tubular reproductive tract of mares during the follicular phase of the oestrous cycle.(73) The maximum levels were found in the follicular fluid, indicating a possible role in ovulation and transport and fertilization of the ova.

### **Roles of CD44 in reproductive pathology**

The CD44 receptor and HA are believed to be associated with reproductive pathology. The CD44 receptor has been implicated in progression and metastasis of ovarian tumors and endometrial carcinomas in women.(24-27) Dilute aqueous solutions or gel formulations of HA can provide a protective tissue coating and have been associated with the prevention of the formation of post surgical adhesions in human and equine patients.(14-17) Gel formulations of HA have proven to reduce post-surgical adhesion formation on the serosa of rabbit uterine horn, (74) mouse uterine horn,(75) and in the cortex of injured ovaries in rabbits.(76) Hyaluronic acid gels significantly reduce the incidence and severity of *de-novo* formation of intrauterine adhesions after hysteroscopic surgery in women.(77) Gels with low concentrations of HA, even as low as a 1% concentration, have also been shown to prevent post-surgical abdominal adhesions. This finding may be of clinical importance in situations where large volumes of anti-adhesive solutions are required.(78)

Although reproductive tract neoplasia is uncommon in mares, chronic degenerative pathologies and adhesions are major causes of infertility, and may be related to the interaction of CD44 and HA. Chronic degenerative disease of the equine endometrium is characterized by uterine gland changes, including cystic dilation,

hyperplasia and periglandular fibrosis. Periglandular fibrosis is reported to be the most common pattern of abnormal fibrinogenesis in the equine endometrium, although fibrosis associated with the luminal epithelium also has been observed.(29) Fibrosis contributes to infertility by interfering with glandular and epithelial function resulting in embryonic death in the first 90 days of gestation.(28) Chronic, inflammatory changes are often identified in older, multiparous mares, although have been observed in young mares. Fibrosis of the endometrium is an irreversible condition and may arise from intrauterine infections, iatrogenic topical therapy or multiple pregnancies. No specific treatment for endometrial fibrosis has proven clinically effective.(28)

### **Technical Considerations**

The expression of CD44 has been demonstrated in equine lymph node, gastrointestinal, and musculoskeletal tissues(52) and in equine melanomas,(79) These studies used immunohistochemical labeling (using mouse anti-CD44 monoclonal antibodies) to identify cell types that express the CD44 receptor. Immunoelectron microscopy was also used to describe the location of the receptor CD44 in relation to the ultrastructural elements of cells of the equine peritoneum and serosa.(52) The primary antibody employed in this study, a rat anti-human panCD44s monoclonal (Chemicon International, Inc, Temecula, CA), is cross-reactive for equine CD44 as indicated by the equine literature.(52) A rabbit anti-rat antibody conjugated to biotin (Vector Labs, Burlingame, CA) was used as a secondary antibody.(52,79)

## **Immunohistochemistry**

Immunohistochemistry is the specific localization of antigens in tissue sections by the use of labeled antibodies as reagents.(80) The antigen-antibody interactions are visualized by a marker such as fluorescent dye, enzyme, radioactive element or colloidal gold. Because IHC involves specific antigen-antibody reactions, it is a more widely applicable technique, allowing the localization of an essentially unlimited number of proteins, when compared to traditional enzyme-based staining techniques.

Heat-induced epitope retrieval (HIER) is a pretreatment procedure often used prior to IHC to improve antibody binding, by modifying the molecular conformation of 'target' proteins by exposure of slide-mounted specimen material (sectioned tissue and other cellular preparations) to a heated buffer solution.(80) These solutions are used to break the protein cross-links caused by formalin fixation and thereby uncover hidden antigenic sites.

Immunohistochemistry relies on the use of one labeled antibody (direct method) or an unlabeled antibody (primary) followed by a labeled secondary antibody (indirect method) to localize the antigen of interest. The later method provides amplification of the signal. Further amplification of signal may be achieved in the indirect method, taking advantage of the very high affinity that avidin has for biotin.. When a biotinylated secondary antibody is used, an avidin-conjugated enzyme binds to the secondary antibody. The avidin-biotin complex method can further increase the specificity and sensitivity of the protocol. Streptavidin can be used as a substitute of avidin, as an uncharged molecule relative to animal tissue. In addition, streptavidin does not contain carbohydrate groups which might bind to tissue lectins, causing background stain. In each



method of IHC, localization of antibody binding is visualized using a substrate chromogen solution, with the production of a colorimetric end product.

### **Immunoelectron microscopy**

Transmission electron microscopy (TEM) is an imaging technique whereby a beam of electrons is transmitted through a specimen, producing an image onto a fluorescent screen or photographic film. The electron gun produces a stream of monochromatic electrons that is focused and condensed using optical lenses over the sample of tissue. The beam strikes the specimen and only parts of it are transmitted into a phosphor image screen producing an image. The dark areas represent those areas of the sample that fewer electrons were transmitted through (thicker areas). The lighter areas represent those areas of the sample that more electrons were transmitted through (thinner areas).(81)

Electron microscopic (EM) immunohistochemical techniques are based on the use of a beam of electrons transmitted through a section of tissue that has been treated with immunological markers to detect the presence of antibodies. Tissues can be incubated with primary antibodies followed by an EM marker, such as a gold-conjugated protein A, to identify the position of the antigen within the structure of a particular cell.(82) Protein A is a bacterial surface protein that is able to bind immunoglobulins (i.e. primary antibodies) with high affinity. Colloidal gold particles can be conjugated to Protein A, producing a dark spot in the EM image that is generated as electrons are deflected.

## **OBJECTIVES**

The objective of this study was to determine the presence and localization of the hyaluronan receptor CD44 in the equine uterus, oviduct and ovary. Identification of the CD44 molecule will provide a base for future research regarding the role of CD44 in fertilization, gestation and treatment of common causes of infertility in the mare and a basis for research in adhesion prevention in horses. This project also expects to optimize reliable protocols to identify the CD44 receptor in other equine tissues.

## **MATERIALS AND METHODS**

### **Animals**

Six adult mares from 4 to 16 years of age were used. The study included mares from different breeds: Thoroughbred, American Quarter Horse and Tennessee walking horse, and in different stages of reproductive activity. The inclusion criteria used the following parameters: (1) older than 3 years of age (to allow mares to have undergone puberty and full development of their reproductive tract) and (2) minimal reproductive tract disease, based on gross necropsy and histologic evaluation.(Table 1)

### **Sample collection**

Samples were obtained from mares that were euthanized after terminal teaching surgeries. The reproductive tracts were examined for gross pathology and activity state. Samples were collected immediately after euthanasia. Samples from the six mares included: (1) Full thickness uterine horn (2 cm x 2 cm), (2) oviduct: infundibulum, ampulla and isthmus (5 mm x 5 mm), (3) ovary: parenchyma and connective tissue capsule (1 cm x 1 cm).

Positive control samples were obtained from the same mares and were processed together with the reproductive tissues. These control tissues included synovium and lymph node that had no gross or histologic evidence of pathology. The samples were duplicated and assigned to two groups: (A) samples to be processed for

immunohistochemistry, and (B) samples to be processed for immunoelectron microscopy. Sections of control tissues and of samples of reproductive tract were stained routinely with hematoxylin and eosin stains and were evaluated for histologic evidence of pathology (inflammation, fibrosis, atrophy) in order to exclude from the study any mares with moderate to severe pathology. The endometrial samples were categorized I-III based on the levels of inflammation, fibrosis and lymphatic stasis.(83) Category I mares are defined as having no endometrial atrophy or hypoplasia during a physiological breeding season. They have >70% chance of producing a live foal. Category II includes mares with slight to moderate, diffuse cellular infiltration with scattered but frequent fibrotic foci with <3 glandular nests per low-power field (in five fields), and mild to moderate lymphatic stasis. Category II can be divided into IIa and IIb based on the Kenney Doig system.(84) Pregnancy rates for mares in category II range from 30 to 70%, depending on the severity of the lesions. Category III mares have histological evidence of irreversible changes such as widespread periglandular fibrosis, severe cellular infiltration and lymphatic stasis. These mares have less than 10% chance of carrying a foal to term.

## **Experimental methods**

### **Immunohistochemistry:**

Samples were sectioned into 2 cm x 2 cm specimens and individually fixed in 10% neutral buffered formalin for 24 hours, then embedded in paraffin blocks. Embedded tissues were sectioned at approximately 5 microns and collected on Vectabond-treated slides (Vector Labs, Burlingame, CA). Slides were placed on a hot plate for 25 minutes at 55-60°C and then cooled for 1 minute. Slides were deparaffinized through xylene (3

changes, 5 minutes each), graded alcohols (80%, 90%, 100% ETOH, 2 min each) and distilled water for 5 minutes.

Slides were introduced in the DAKO Autostainer (Universal Staining System) where they underwent the following sequence: incubation with 100  $\mu$ l of PBA (protein blocking agent, Lipshaw, Pittsburg, PA) for 2 minutes at room temperature, rinsed and incubated with the primary antibody (Rat anti-CD44s monoclonal antibody; Chemicon International, Inc, Temecula, CA) at a dilution of 1:1000 with 0.01M PBS for 60 minutes at room temperature. The slides were rinsed and placed in PBS/T (0.5% Tween 20 in 1 L 0.01M PBS) for 15 minutes. The secondary antibody, a rabbit, anti-rat antibody (Vector Biotinylated Rabbit anti-Rat monoclonal antibody, Vector Labs) was incubated with 2% normal horse serum (Vector Labs) for 30 minutes prior to application on the slides, in order to reduce non-specific binding of the secondary antibody to horse tissues. The anti-rat secondary antibody was applied (diluted to 7  $\mu$ g/ml in 0.01M PBS) to the tissue sections, and the slides were incubated for 15 minutes at room temperature. After a PBS/T washing step, Streptavidin-AP (DAKO, Carpinteria, CA), diluted 1:200 in Tris-HCL, was applied and slides were incubated for 30 minutes at 37°C. Slides were rinsed and washed in distilled water for 5 minutes.

The chromogen, Fuschin (DAKO, Carpinteria, CA) was applied for 10 minutes at room temperature. The slides were monitored via light microscopy for development of chromogen, then washed with distilled water for 5 minutes and counterstained with hematoxylin (Gill's 1, Fischer Scientific, Houston, TX) with 100  $\mu$ l/slide for 20-30 seconds. The slides were rinsed and blued in running tap water for 5 minutes. Finally, the slides were dehydrated through graded alcohols to xylene and mounted with Permount

(Fisher Scientific, Houston, TX). Positive and negative control slides were prepared in parallel to study samples (negative controls were not incubated with primary antibody). Rat IgG2b directed to rat monoclonal antibodies was used as a (negative) isotype control.

Slides were evaluated under light microscopy for binding of specific antibody. Results were described according to stain identification, subcellular location, and intensity of stain (strong, moderate and weak). The description of strong was assigned to an intensity equivalent to that identified in lymphocytes and synoviocytes.

#### **Immunoelectron microscopy:**

Samples were sectioned into 1mm x 2mm specimens and then individually fixed in 0.1% glutaraldehyde, 4% formalin in phosphate buffer solution at pH 7.4. After fixation for a minimum of 4 hours, specimens were washed with the phosphate buffer, post-fixed in 1% osmium tetroxide in phosphate for 1 hour, washed in double-distilled water and dehydrated in graded alcohols. The specimens were infiltrated with 70% ETOH:LH White, followed by 100% LR White for 24 hours at room temperature.

The grids were oven-cured at 45°C and 65°C for 24 hours each. Post-aldehyde fixation was performed and the grids were washed with incubation buffer or IB (150 µl of 10% BSA-c: Electron Microscopy Sciences, Ft. Washington, PA) for 5 minutes. Grids were incubated with Rat anti-CD44s monoclonal (Chemicon International, Inc., Temecula, CA) diluted 2µl/ml with incubation buffer (IB) as the primary antibody at 4° C overnight. Grids were washed with IB for 5 minutes, 6 times. Incubation with 10 nm of gold-conjugated protein A (Sigma Chemicon Corporation, St. Louis, MO) diluted 1:40 with IB was carried out for 2 hours and then IB washes were repeated. Grids were post-

fixed with 5% glutaraldehyde (with PBS) for 5 minutes, washed with PBS and distilled water. Grids were contrasted using standard staining with 2% aqueous uranyl acetate and 0.4% lead citrate.

Grids were evaluated with a Philips 301 Transmission Electron Microscope at 60 Kv. The ultrastructural location of accumulated gold particles was determined for each cell type. Results were recorded photographically.

## **RESULTS**

### **Hematoxylin-eosin evaluation**

The samples of hematoxylin and eosin-stained reproductive tract from the 6 mares were examined histologically. The endometrial samples were categorized I-III based on the levels of inflammation, fibrosis. Four mares were categorized as I and two mares as category IIa. Moderate or severe endometrial pathology (inflammation, fibrosis, or atrophy) was not observed.

### **Immunohistochemistry**

Both positive and negative control procedures were used to validate the immunohistochemical staining process. Controls slides, incubated with rat isotype control, did not have chromogen deposition, confirming the specificity of the stain. Both synovium and lymph node demonstrated strong positive immunostaining for CD44, confirming an adequate staining protocol. Type B synoviocytes, fibroblasts and lymphocytes had positive immunostaining that was localized to the cytoplasm and cell membrane. The stain intensity identified in these cells was designated as intense for comparison purposes with the study tissues.

In pilot studies aimed at optimization of the IHC protocol, the demonstration of the CD44 antigen expression was markedly improved by pretreatment of the tissue sections with an antigen retrieval solution subjected to heat (HIER). In addition, equine



serum was used to block non-specific background staining caused by non-immunological binding of antibodies to tissue sections hydrophobic and electrostatic forces.

. Positive CD44 immunolabelling was present in at least one cell population in all of the control and study tissues evaluated. Lymphocytes and plasma cells were present in the epithelium and in small numbers in the stroma of all tissues examined. This cell population was used as a positive internal control. (Table 2)

The serosal surfaces of the reproductive tissues presented as intermittent monolayers of intensely positive cells. Both cell membrane and cytoplasm contained uniform stain. All tissues contained small numbers of lymphocytes and fibroblasts with uniform intense positive stains, identical to that observed in the lymph node and synovium preparations.

The ovarian serosa, medulla, and cortex contained CD44 immunoreactivity in differing degrees. The medulla and cortex had mild staining, with increased intensity in follicular structures. The secondary and tertiary follicles contained mild antral fluid stain. The granulosa cells presented a moderate stain concentrated in the luminal membrane. The internal thecal cells had a mild stain to no staining in smaller follicles. The outer thecal cells had a more intense stain in larger follicles. Fibroblasts were graded as moderately to intensely positive. Luteal cells, primary follicles and oocytes were not observed in the examined sections.

Positive staining for CD44 was identified in cells of all layers of the infundibulum, ampulla and isthmus. The stain was scored as moderately positive in cells in all the oviductal tunics and intensely positive in the serosal surfaces. The luminal epithelium was positive for CD44 with decreasing intensity from intense in the

infundibulum to moderate in the isthmus. This stain was confined to the ad-luminal and basolateral membranes and the supra-nuclear regions. The areas of higher antibody uptake were found on the basal surface of the tubular epithelial cells throughout the oviductal luminal epithelium, especially of the secretory cells. (Figs.1a and 1b). The cilia did not bind anti-CD44 antibody.

The CD44 molecule was localized primarily in the uterine endometrium but not uniformly in the uterine glands (Figs. 2a-c). Expression of CD44 is prominent in surface endometrial cells, reaching a more intense stain as the uterine endometrial cells grew taller and columnar in the different regions of the endometrium. Variations in surface endometrial epithelium and staining intensity were moderate between mares. The uterine gland epithelium did not express CD44, but small numbers of lymphocytes in the glandular lining did bind antibody to CD44. Intense immunostaining was observed in areas of periglandular fibrosis and by lymphocytes in scattered foci of inflammation in the uterus of two mares. Uniformly, the myometrium did not stain for CD44.

### **Immunoelectron microscopy**

The luminal epithelium of the infundibulum of the oviduct was examined with EM, as this was the area with the most intense localized immunostaining. The images showed a non-specific localization of Protein A-gold colloid within the epithelial cells. The colloid was identified in the cellular surfaces and the extracellular matrices, as well as fibroblasts in the lamina propria.

In the epithelial cells, aggregates and individual particles (interpreted to reflect individual and groups of CD44 molecules) could be identified in the cellular membrane,

cytosol and nucleus. This uptake did not seem to follow any pattern of known intracellular transport, although some could be related to ribosomal structures and cytoskeletal elements, such as gold particles that were present at the base of some cilia.

No difference could be observed between the disposition of the Protein A-gold colloid particles in the ciliated and secretory cell at the EM level. On the other hand, the colloid particles were absent from the cilia, as observed with light microscopy.

## **DISCUSSION**

The present study demonstrates the presence and localization of the hyaluronan receptor CD44 in the reproductive tract of the mare. CD44 was identified in the ovaries, oviducts and uterus of six mares. The receptor was distributed mainly throughout the luminal epithelia and on serosal surfaces. This finding may guide the development of clinical applications that modulate the CD44-HA signaling process in equine theriogenology and surgery.

In this study, the ovarian serosa, medulla and cortex express CD44 to different degrees. The medulla and cortex had a low CD44 expression with increasing intensity in follicular structures and antral fluid, suggesting a role of CD44 in follicular and oocyte development. The granulosa cells express moderate levels of CD44 that are concentrated in the luminal membrane, indicating a possible interaction between the antral fluid HA and CD44 receptors on the granulosa cells. The internal thecal cells express little to no CD44 in smaller follicles. The outer, fibroblast-like, thecal cells of large follicles express CD44 at moderate to intense levels. Outer thecal cells function in vascular and connective tissue deposition around the maturing follicle. Follicular rupture and ovulation have been considered forms of inflammation, as they rely on an inflammatory infiltration of theca cells for the release of follicular contents.(28) Based on the well known functions of the CD44-HA system in inflammation, cellular migration, and matrix development, we

anticipate a relationship between the intense CD44 expression by outer theca cells and the surrounding connective tissues and follicular rupture and ovulation.

The extensive localization of CD44 in the luminal epithelia of the oviduct and uterus in this study suggests a role of the CD44-HA interaction in the fertilization and embryonic events in the mare. The immuno-localization of CD44 in the oviduct coincides with that described in the pig and bovine (67,68), indicating that there may be a common reproductive function of this receptor-ligand system. The specific localization of CD44 in the secretory epithelial cells of the equine oviduct may indicate the possible role of CD44 in the uptake and degradation of HA from the equine oviductal fluid. This localization is related to the involvement of HA metabolism from the oviductal fluid in the bovine.(2) In contrast to the expression of CD44 by secretory epithelial cells of the equine oviduct, the ciliated tubal cells present only basal or baso-lateral stain. The absence of stain in the cilia and luminal surfaces may be related to the propulsive functions of these structures, preventing adhesion of the oocyte or developing embryo to the oviduct wall.

The presence of CD44 in the cytoplasm of the endometrial, oviductal and ovarian cells may represent evidence of an intracellular domain or location of CD44. Further research is needed to elucidate a relationship of this location with signaling between HA and cytoskeleton proteins.

Various isoforms of CD44 have been identified in the endometrium of women and of various laboratory species. Functions of CD44 in this tissue include: maintenance of the integrity of the epithelial sheet, modulation of cell invasion and migratory capacities during menstrual re-epithelization and embryo implantation.(10,13,20-23) Expression of isoforms of CD44 were restricted to the basal and luminal areas of the

epithelia of the human endometrium in one study (85), but were routinely identified in the basolateral surface of the endometrium of pregnant and non-pregnant women (62), and in the equine endometrium in our study. Given the differences in endometrial disposition in human beings and mares, CD44 was expected to be expressed in different areas as shown by this study. The human endometrium undergoes dramatic remodeling during the course of the normal menstrual cycle, but the regulation of this process is not completely understood. The dramatic changes in hyaluronan deposition and the correlation of HA with cyclic growth and remodeling in the human endometrium suggests a major role for hyaluronan in the physiology of this tissue.(86) The equine endometrium does not undergo such a dramatic remodeling, only changing transitionally from cuboidal to tall columnar cells, depending on the stage of the of the estrous cycle. The increased CD44 expression by surface columnar cells in the mare endometrium may imply a preparation for embryo implantation and trophoblast development.

The equine embryo migrates throughout the uterus until Day 15, when it comes to rest at the caudal end of one of the horns, occupying a nidation chamber.(87,88) Uniform CD44 expression was found throughout the endometrium of the caudal end of the uterine horns. This finding suggests a role of the CD44-HA interaction in the implantation of the equine embryo in this area.

Hyaluronan and CD44 are expressed in the human trophoblast where they are believed to participate in the invasion of the endometrium.(64) The invasion of the equine endometrium by the trophoblast cells around Day 36 is initiated by the destruction of the endothelium and further establishment in the endometrial stroma.(89) A relationship may exist between the intensity of CD44 in the equine endometrium, as identified in this

study, and the success of trophoblast invasion. Further research is needed to study the roles of HA and CD44 in the pregnant equine uterus.

The trophoblast cells become surrounded by a wall of lymphocytes when they reach the uterine connective tissue.(88) Expression of CD44 was found consistently in the equine uterine connective tissue and lymphocytes of the uterine stroma. Based on the role of CD44 in lymphocyte migration,(5) a relationship may exist between this finding and the recognition and surrounding of the trophoblast cells by lymphocytes. A strong leukocytic response is also related to necrosis and sloughing of the trophoblast or endometrial cups by Day 130 in the mare.(28) The mechanism of their demise is not well known. Signaling by CD44 may be involved in the regulation of apoptotic cell clearance. Studies in mice with targeted deletions of several exons of the CD44 gene were associated with an increase in apoptosis of infiltrating cells. (8) CD44 may regulate cell survival and clearance of apoptotic leukocytes during the evolution of an inflammatory response.(8)

The CD44 molecule was expressed minimally in the uterine glands, with only 1 to 3 cells per gland demonstrating positive stain. This finding correlates with observations made in human endometrium where coding sequence for the CD44H isoform was absent, or very scarce, in a cDNA library produced from purified gland epithelium.(62) The use of HA preparations locally or systemically may aid in the prevention of fibrosis. For this purpose, future research should be performed on the expression of CD44 and on CD44-HA interactions in mares suffering from endometrial pathology.

Similar studies have described CD44 in equine melanomas,(79) lymph nodes, gastrointestinal and synovial tissues.(52) These studies used immunohistochemical

labeling to identify the cell types that contain the CD44 receptor in a protocol similar to that used in this study.(52,79) Immunoelectron microscopy has been used to describe the location of the receptor CD44 in relation to the ultrastructure of equine mesothelial cells.(52) The distribution of the Protein A-gold particles in our study could not be correlated with the known or expected intracellular distribution of CD44. The reason for the conflicting labeling results between the two studies may be related to the presence of receptors with similar antigenic sites to CD44 (other HA receptors like RHAMM and TSG-6)(4) in the equine oviduct, that may not present in the equine mesothelium, and to differences in fixation and processing.

Considering the information available and the results of this study, the localization of CD44 suggests an important role of the CD44-HA pathway in reproductive events like sperm storage, maturation, capacitation, and fertilization, as well as in ovulation and trophoblast implantation. In addition, the confirmation of the expression of CD44 by leukocytes and by serosal lining cells in the equine abdomen is an important foundation for future studies investigating the therapeutic modulation of this signaling pathway.



## REFERENCES

1. Alho AM, Underhill CB. The hyaluronate receptor is preferentially expressed on proliferating epithelial cells. *J Cell Biol* 1989;108: 1557-1565.
2. Bergqvist AS, Yokoo M, Bage R, Sato E, Rodriguez-Martinez H. Detection of the Hyaluronan Receptor CD44 in the Bovine Oviductal Epithelium. *J Reprod Dev* 2005.
3. Gallatin WM RS, Ganji A, et al. Structure-function relationships of the CD44 class of glycoproteins. Cellular and molecular mechanisms of inflammation, Academic Press 1991;2: 131-151.
4. Underhill C. CD44: the hyaluronan receptor. *J Cell Sci* 1992;103 ( Pt 2): 293-298.
5. Bajorath J. Molecular organization, structural features, and ligand binding characteristics of CD44, a highly variable cell surface glycoprotein with multiple functions. *Proteins* 2000;39: 103-111.
6. Culty M, Nguyen HA, Underhill CB. The hyaluronan receptor (CD44) participates in the uptake and degradation of hyaluronan. *J Cell Biol* 1992;116: 1055-1062.
7. Borland G, Ross JA, Guy K. Forms and functions of CD44. *Immunology* 1998;93: 139-148.
8. Pure E, Cuff CA. A crucial role for CD44 in inflammation. *Trends Mol Med* 2001;7: 213-221.

9. Svec K, White J, Vaillant P, Jessurun J, Roongta U, Krumwiede M, Johnson D, Henke C. Acute lung injury fibroblast migration and invasion of a fibrin matrix is mediated by CD44. *J Clin Invest* 1996;98: 1713-1727.
10. Wayner EA, Carter WG. Identification of multiple cell adhesion receptors for collagen and fibronectin in human fibrosarcoma cells possessing unique alpha and common beta subunits. *J Cell Biol* 1987;105: 1873-1884.
11. Jiang D LJ, Noble PW. Hyaluronan in Tissue Injury and Repair. *Annu Rev Cell Dev Biol* 2006.
12. Boraldi F. Cell-matrix interactions of in vitro human skin fibroblasts upon addition of hyaluronan. *Tissue & Cell* 2003;35: 37-45.
13. Ehnis T, Dieterich W, Bauer M, Lampe B, Schuppan D. A chondroitin/dermatan sulfate form of CD44 is a receptor for collagen XIV (undulin). *Exp Cell Res* 1996;229: 388-397.
14. Balazs EA, Denlinger JL. Clinical uses of hyaluronan. *Ciba Found Symp* 1989;143: 265-275; discussion 275-280, 281-265.
15. Muller SA, Treutner KH, Haase G, Kinzel S, Tietze L, Schumpelick V. Effect of intraperitoneal antiadhesive fluids in a rat peritonitis model. *Arch Surg* 2003;138: 286-290.
16. Mueller PO, Hay WP, Harmon B, Amoroso L. Evaluation of a bioresorbable hyaluronate-carboxymethylcellulose membrane for prevention of experimentally induced abdominal adhesions in horses. *Vet Surg* 2000;29: 48-53.
17. Kutlay J, Ozer Y, Isik B, Kargici H. Comparative effectiveness of several agents for preventing postoperative adhesions. *World J Surg* 2004;28: 662-665.

18. Aytekin FO, Tekin K, Kabay B, Erdem E, Erbis H, Ozden A. Role of a hyaluronic-acid derivative in preventing surgical adhesions and abscesses related to dropped bile and gallstones in an experimental model. *Am J Surg* 2004;188: 288-293.
19. Himeda Y, Yanagi S, Kakema T, Fujita F, Umeda T, Miyoshi T. Adhesion preventive effect of a novel hyaluronic acid gel film in rats. *J Int Med Res* 2003;31: 509-516.
20. Liao HX, Lee DM, Levesque MC, Haynes BF. N-terminal and central regions of the human CD44 extracellular domain participate in cell surface hyaluronan binding. *J Immunol* 1995;155: 3938-3945.
21. Peach RJ, Hollenbaugh D, Stamenkovic I, Aruffo A. Identification of hyaluronic acid binding sites in the extracellular domain of CD44. *J Cell Biol* 1993;122: 257-264.
22. Jalkanen S, Jalkanen M. Lymphocyte CD44 binds the COOH-terminal heparin-binding domain of fibronectin. *J Cell Biol* 1992;116: 817-825.
23. Weber GF, Ashkar S, Glimcher MJ, Cantor H. Receptor-ligand interaction between CD44 and osteopontin (Eta-1). *Science* 1996;271: 509-512.
24. Saegusa M, Machida D, Hashimura M, Okayasu I. CD44 expression in benign, premalignant, and malignant ovarian neoplasms: relation to tumour development and progression. *J Pathol* 1999;189: 326-337.
25. Saegusa M, Hashimura M, Machida D, Okayasu I. Down-regulation of CD44 standard and variant isoforms during the development and progression of uterine cervical tumours. *J Pathol* 1999;187: 173-183.

26. Qu P, Jiao S, Gao Q. [Clinical significance of CD44 expression in ovarian epithelial tumors]. *Zhonghua Zhong Liu Za Zhi* 2001;23: 46-49.
27. Stokes GN, Shelton JB, Jr., Zahn CM, Kendall BS. Association of CD44 isoform immunohistochemical expression with myometrial and vascular invasion in endometrioid endometrial carcinoma. *Gynecol Oncol* 2002;84: 58-61.
28. McKinnon A. *Equine Reproduction*: Lea & Febiger, 1993.
29. Evans TJ, Miller MA, Ganjam VK, Niswender KD, Eilersieck MR, Krause WJ, Youngquist RS. Morphometric analysis of endometrial periglandular fibrosis in mares. *Am J Vet Res* 1998;59: 1209-1214.
30. Butson RJ, England GC, Blackmore CA. Omento-omental adhesion around the uterine horn as a cause of recurrent colic in a mare. *Vet Rec* 1996;139: 571-572.
31. Allen W. Equine Endometritis. *Proceedings of the John P. Hughes International Workshop on Equine Endometritis*, 1993;184-193.
32. Aplin JD. Adhesion molecules in implantation. *Rev Reprod* 1997;2: 84-93.
33. Sneath RJ, Mangham DC. The normal structure and function of CD44 and its role in neoplasia. *Mol Pathol* 1998;51: 191-200.
34. Horne AW, White JO, Lalani el N. Adhesion molecules and the normal endometrium. *Bjog* 2002;109: 610-617.
35. Lishanthi Udabage ea. Inhibition of hyaluronan degradation by dextran sulphate facilitates characterisation of hyaluronan synthesis: An in vitro and in vivo study. *Glycoconjugate Journal* 2004;20: 461-471.
36. Evanko SP, Wight TN. Intracellular localization of hyaluronan in proliferating cells. *J Histochem Cytochem* 1999;47: 1331-1342.

37. Randall B, Eggleston EM. Prevention and treatment of gastrointestinal adhesions. *Vet Clin Equine* 2003;19: 741-763.
38. Thorne RF, Legg JW, Isacke CM. The role of the CD44 transmembrane and cytoplasmic domains in co-ordinating adhesive and signalling events. *J Cell Sci* 2004;117: 373-380.
39. Bradbury J. A therapeutic future for CD44 in inflammation? *Lancet* 2002;359: 2008.
40. Leblanc M, Poncelet C, Soriano D, Walker-Combrouze F, Madelenat P, Scoazec JY, Darai E. Alteration of CD44 and cadherins expression: possible association with augmented aggressiveness and invasiveness of endometrial carcinoma. *Virchows Arch* 2001;438: 78-85.
41. Poncelet C, Leblanc M, Walker-Combrouze F, Soriano D, Feldmann G, Madelenat P, Scoazec JY, Darai E. Expression of cadherins and CD44 isoforms in human endometrium and peritoneal endometriosis. *Acta Obstet Gynecol Scand* 2002;81: 195-203.
42. Kaneko T, Saito H, Toya M, Satio T, Nakahara K, Hiroi M. Hyaluronic acid inhibits apoptosis in granulosa cells via CD44. *J Assist Reprod Genet* 2000;17: 162-167.
43. Jones M, Tussey L, Athanasou N, Jackson DG. Heparan sulfate proteoglycan isoforms of the CD44 hyaluronan receptor induced in human inflammatory macrophages can function as paracrine regulators of fibroblast growth factor action. *J Biol Chem* 2000;275: 7964-7974.

44. Knudson W, Chow G, Knudson CB. CD44-mediated uptake and degradation of hyaluronan. *Matrix Biol* 2002;21: 15-23.
45. Eggleston R. B. EM. Prevention and treatment of gastrointestinal adhesions. *Vet Clin Equine* 2003;19: 741-763.
46. Mayer M, Yedgar S, Hurwitz A, Palti Z, Finzi Z, Milwidsky A. Effect of viscous macromolecules on peritoneal plasminogen activator activity: a potential mechanism for their ability to reduce postoperative adhesion formation. *Am J Obstet Gynecol* 1988;159: 957-963.
47. Goodrich L N. Medical treatment of osteoarthritis in horses. *The Veterinary Journal* 2004.
48. Tulamo RM, Heiskanen T, Salonen M. Concentration and molecular weight distribution of hyaluronate in synovial fluid from clinically normal horses and horses with diseased joints. *Am J Vet Res* 1994;55: 710-715.
49. Salmi M, Jalkanen S. Human leukocyte subpopulations from inflamed gut bind to joint vasculature using distinct sets of adhesion molecules. *J Immunol* 2001;166: 4650-4657.
50. Bauer S, Jendro MC, Wadle A, Kleber S, Stenner F, Dinser R, Reich A, Faccin E, Godde S, Dinges H, Muller-Ladner U, Renner C. Fibroblast activation protein is expressed by rheumatoid myofibroblast-like synoviocytes. *Arthritis Res Ther* 2006;8: R171.
51. Suzuki A, Nozawa-Inoue K, Amizuka N, Ono K, Maeda T. Localization of CD44 and hyaluronan in the synovial membrane of the rat temporomandibular joint. *Anat Rec A Discov Mol Cell Evol Biol* 2006;288: 646-652.

52. Frees KE. The presence of hyaluronan receptors in equine serosa and peritoneum, *Clinical Sciences*. Manhattan: Kansas State University, 2001;1-63.
53. Banks W. *Applied Veterinary Histology*, Third edition. St.Louis: Mosby, 1993;222.
54. Burkitt H. *Wheater's Functional Histology*, Third edition. London: Churchill Livingstone, 1993;188.
55. Graabaek PM. Characteristics of the two types of synoviocytes in rat synovial membrane. An ultrastructural study. *Lab Invest* 1984;50: 690-702.
56. Edwards JC. The origin of type A synovial lining cells. *Immunobiology* 1982;161: 227-231.
57. Revell PA. Synovial lining cells. *Rheumatol Int* 1989;9: 49-51.
58. Jalkanen ST, Bargatze RF, Herron LR, Butcher EC. A lymphoid cell surface glycoprotein involved in endothelial cell recognition and lymphocyte homing in man. *Eur J Immunol* 1986;16: 1195-1202.
59. DeGrendele HC, Estess P, Picker LJ, Siegelman MH. CD44 and its ligand hyaluronate mediate rolling under physiologic flow: a novel lymphocyte-endothelial cell primary adhesion pathway. *J Exp Med* 1996;183: 1119-1130.
60. Gardner MJ, Catterall JB, Jones LM, Turner GA. Human ovarian tumour cells can bind hyaluronic acid via membrane CD44: a possible step in peritoneal metastasis. *Clin Exp Metastasis* 1996;14: 325-334.
61. Woerner SM, Givehchian M, Durst M, Schneider A, Costa S, Melsheimer P, Lacroix J, Zoller M, Doeberitz MK. Expression of CD44 splice variants in

- normal, dysplastic, and neoplastic cervical epithelium. *Clin Cancer Res* 1995;1: 1125-1132.
62. Behzad F, Seif MW, Campbell S, Aplin JD. Expression of two isoforms of CD44 in human endometrium. *Biol Reprod* 1994;51: 739-747.
63. Ohta N, Saito H, Kaneko T, Yoshida M, Takahashi T, Saito T, Nakahara K, Hiroi M. Soluble CD44 in human ovarian follicular fluid. *J Assist Reprod Genet* 2001;18: 21-25.
64. Goshen R, Ariel I, Shuster S, Hochberg A, Vlodaysky I, de Groot N, Ben-Rafael Z, Stern R. Hyaluronan, CD44 and its variant exons in human trophoblast invasion and placental angiogenesis. *Mol Hum Reprod* 1996;2: 685-691.
65. Ohta N, Saito H, Kuzumaki T, Takahashi T, Ito MM, Saito T, Nakahara K, Hiroi M. Expression of CD44 in human cumulus and mural granulosa cells of individual patients in in-vitro fertilization programmes. *Mol Hum Reprod* 1999;5: 22-28.
66. Bains R, Adeghe J, Carson RJ. Human sperm cells express CD44. *Fertil Steril* 2002;78: 307-312.
67. Tienthai P, Kimura N, Heldin P, Sato E, Rodriguez-Martinez H. Expression of hyaluronan synthase-3 in porcine oviducal epithelium during oestrus. *Reprod Fertil Dev* 2003;15: 99-105.
68. Ulbrich SE, Schoenfelder M, Thoene S, Einspanier R. Hyaluronan in the bovine oviduct--modulation of synthases and receptors during the estrous cycle. *Mol Cell Endocrinol* 2004;214: 9-18.



69. Yokoo M, Tientha P, Kimura N, Niwa K, Sato E, Rodriguez-Martinez H. Localisation of the hyaluronan receptor CD44 in porcine cumulus cells during in vivo and in vitro maturation. *Zygote* 2002;10: 317-326.
70. Furnus CC, Valcarcel A, Dulout FN, Errecalde AL. The hyaluronic acid receptor (CD44) is expressed in bovine oocytes and early stage embryos. *Theriogenology* 2003;60: 1633-1644.
71. Bergqvist AS, Ballester J, Johannisson A, Hernandez M, Lundeheim N, Rodriguez-Martinez H. In vitro capacitation of bull spermatozoa by oviductal fluid and its components. *Zygote* 2006;14: 259-273.
72. Lee CN, Ax RL. Concentrations and composition of glycosaminoglycans in the female bovine reproductive tract. *J Dairy Sci* 1984;67: 2006-2009.
73. Varner DD, Forrest DW, Fuentes F, Taylor TS, Hooper RN, Brinsko SP, Blanchard TL. Measurements of glycosaminoglycans in follicular, oviductal and uterine fluids of mares. *J Reprod Fertil Suppl* 1991;44: 297-306.
74. Leach RE, Burns JW, Dawe EJ, SmithBarbour MD, Diamond MP. Reduction of postsurgical adhesion formation in the rabbit uterine horn model with use of hyaluronate/carboxymethylcellulose gel. *Fertil Steril* 1998;69: 415-418.
75. Sawada T, Tsukada K, Hasegawa K, Ohashi Y, Udagawa Y, Gomel V. Cross-linked hyaluronate hydrogel prevents adhesion formation and reformation in mouse uterine horn model. *Hum Reprod* 2001;16: 353-356.
76. Meyer WR, Grainger DA, DeCherney AH, Lachs MS, Diamond MP. Ovarian surgery on the rabbit. Effect of cortex closure on adhesion formation and ovarian function. *J Reprod Med* 1991;36: 639-643.

77. Guida M, Acunzo G, Di Spiezio Sardo A, Bifulco G, Piccoli R, Pellicano M, Cerrota G, Cirillo D, Nappi C. Effectiveness of auto-crosslinked hyaluronic acid gel in the prevention of intrauterine adhesions after hysteroscopic surgery: a prospective, randomized, controlled study. *Hum Reprod* 2004;19: 1461-1464.
78. Belluco C, Meggiolaro F, Pressato D, Pavesio A, Bigon E, Dona M, Forlin M, Nitti D, Lise M. Prevention of postsurgical adhesions with an autocrosslinked hyaluronan derivative gel. *J Surg Res* 2001;100: 217-221.
79. Seltenhammer MH, Heere-Ress E, Brandt S, Druml T, Jansen B, Pehamberger H, Niebauer GW. Comparative histopathology of grey-horse-melanoma and human malignant melanoma. *Pigment Cell Res* 2004;17: 674-681.
80. Javois LC. *Immunocytochemical methods and protocols.*, 2nd Edition edition. New Jersey: Humana Press.
81. J. Polak LMV. *Immunolabeling for electron microscopy.*: Elsevier Science Publishers.
82. Beesley J. *Colloidal Gold: a new perspective for cytochemical marking.*, Volume 17. Oxford: Oxford University Press, 1989.
83. Kenney RM. Cyclic and pathologic changes of the mare endometrium as detected by biopsy, with a note on early embryonic death. *J Am Vet Med Assoc* 1978;172: 241-262.
84. Waelchli RO. Endometrial biopsy in mares under nonuniform breeding management conditions: prognostic value and relationship with age. *Can Vet J* 1999;31: 379-384.

85. Terpe HJ, Stark H, Prehm P, Gunthert U. CD44 variant isoforms are preferentially expressed in basal epithelial of non-malignant human fetal and adult tissues. *Histochemistry* 1994;101: 79-89.
86. Salamonsen LA, Shuster S, Stern R. Distribution of hyaluronan in human endometrium across the menstrual cycle. Implications for implantation and menstruation. *Cell Tissue Res* 2001;306: 335-340.
87. Ginther OJ. Fixation and orientation of the early equine conceptus. *Theriogenology* 1983;19: 613-623.
88. Enders AC, Liu IK. Lodgement of the equine blastocyst in the uterus from fixation through endometrial cup formation. *J Reprod Fertil Suppl* 1991;44: 427-438.
89. Allen WR, Hamilton DW, Moor RM. The origin of equine endometrial cups. II. Invasion of the endometrium by trophoblast. *Anat Rec* 1973;177: 485-501.

## FIGURES

(a)

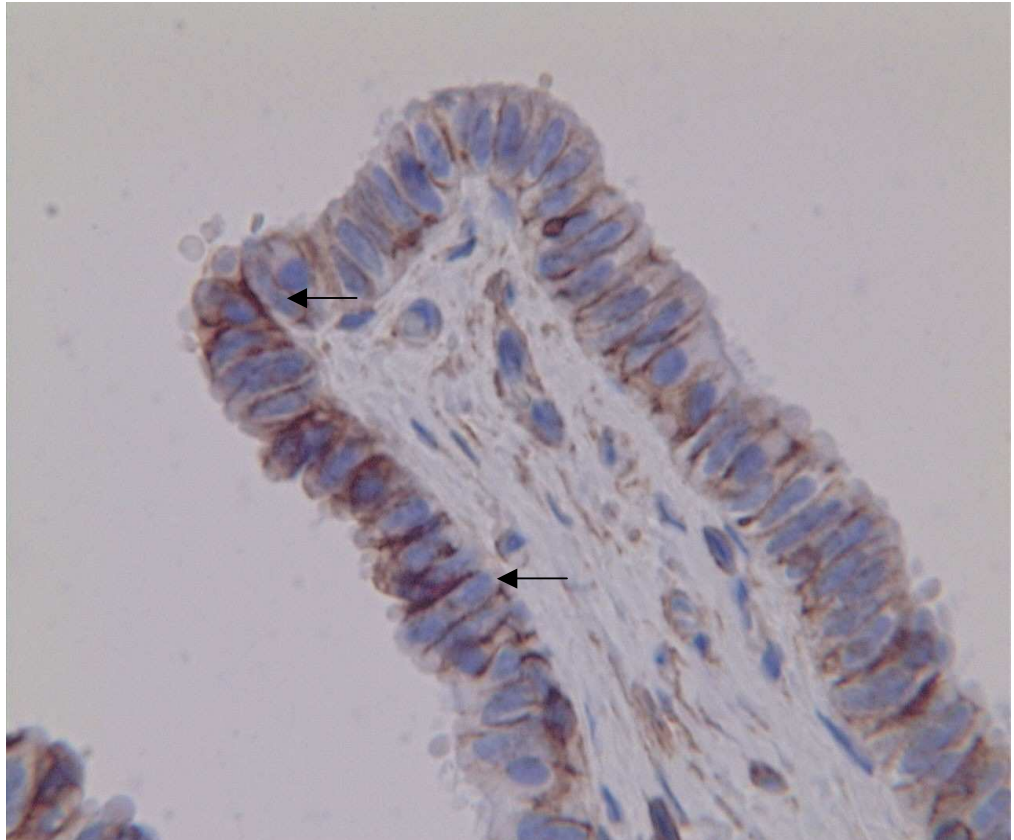


Figure 1a: Immunolabelling for CD44 of the equine oviduct. (a) Infundibulum, x 100, Black arrows depict CD44-positive staining in the basolateral membranes and supranuclear regions of the ciliated cells.

(b)

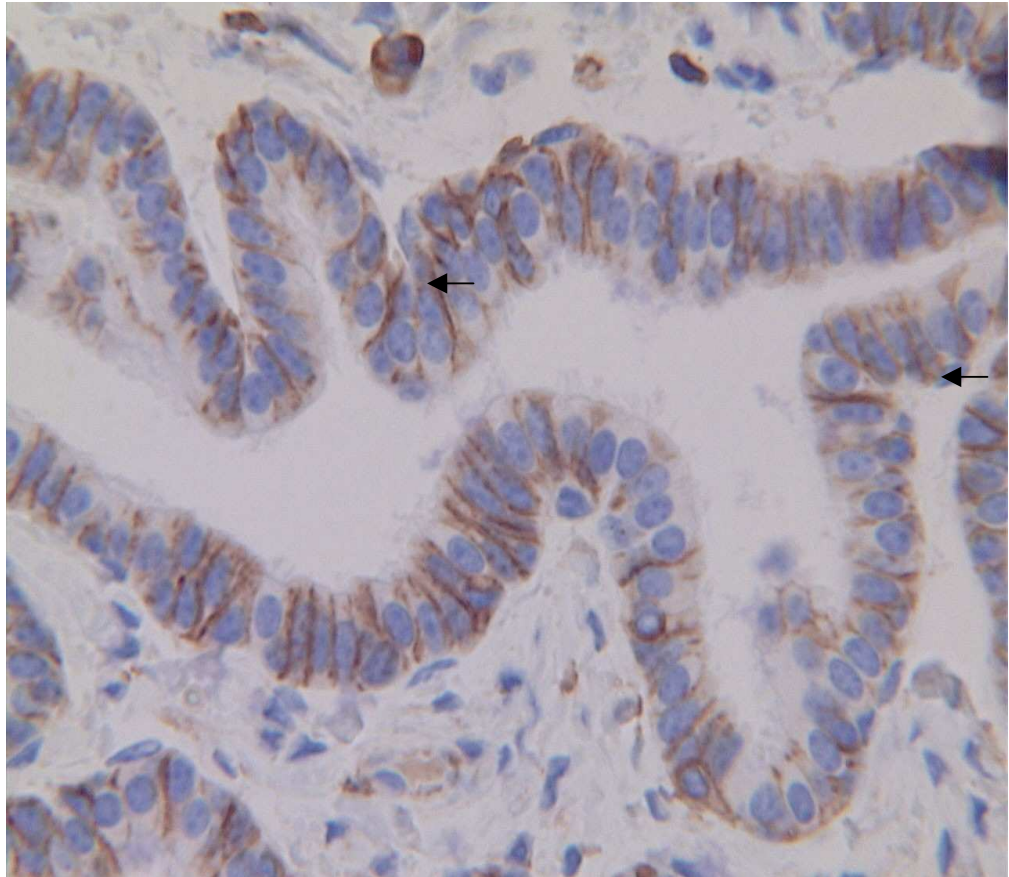


Figure 1b: Immunolabelling for CD44 of the equine oviduct. Ampulla, x 100.

Black arrows depict CD44-positive staining of the non-ciliated, secretory cells. The stain is localized mainly in the basolateral membranes.

(c)

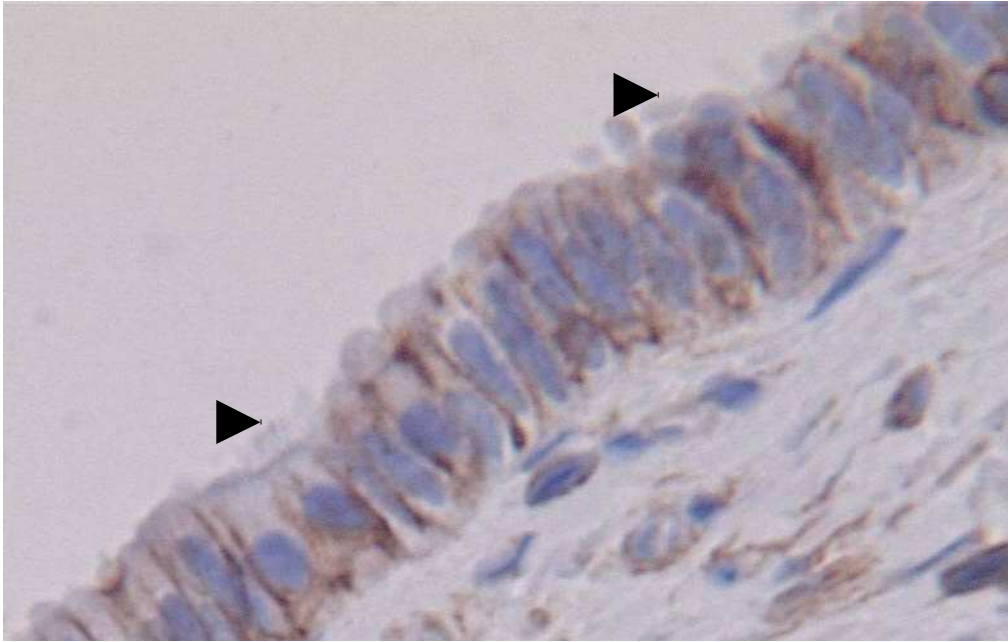


Figure.1c: Immunolabelling for CD44 of the equine oviduct. Infundibular cilia, x 100.

Arrow heads highlight absence of CD44-staining in the cilia.



(a)

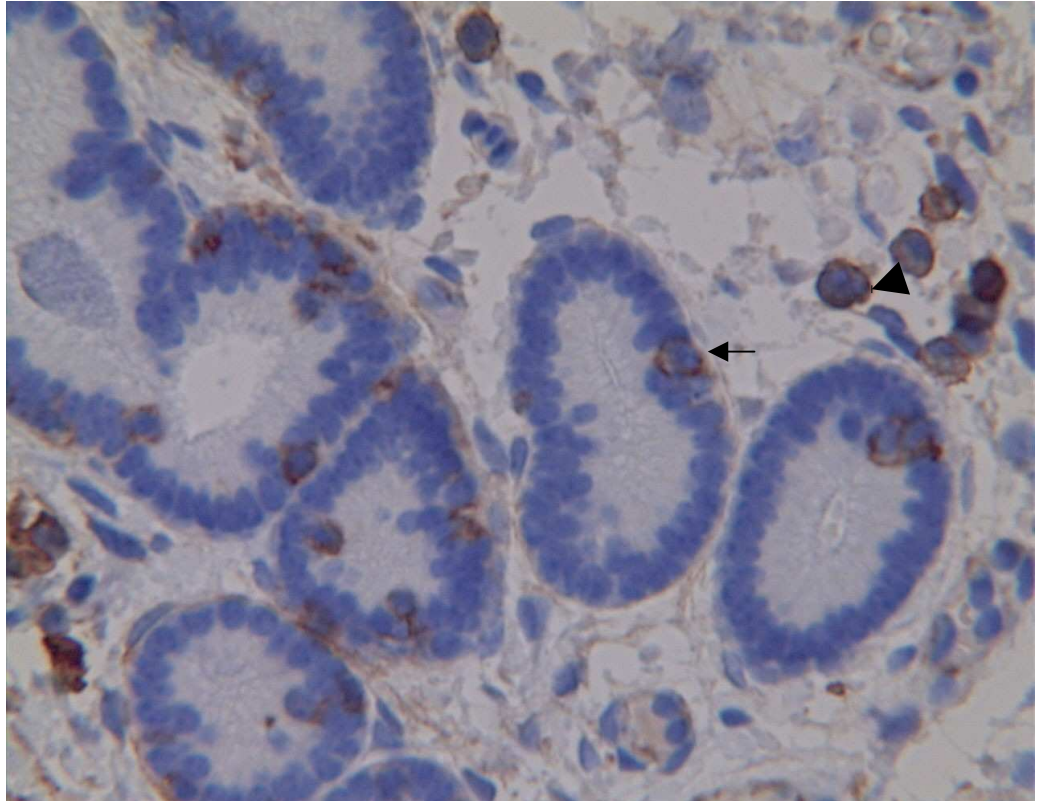
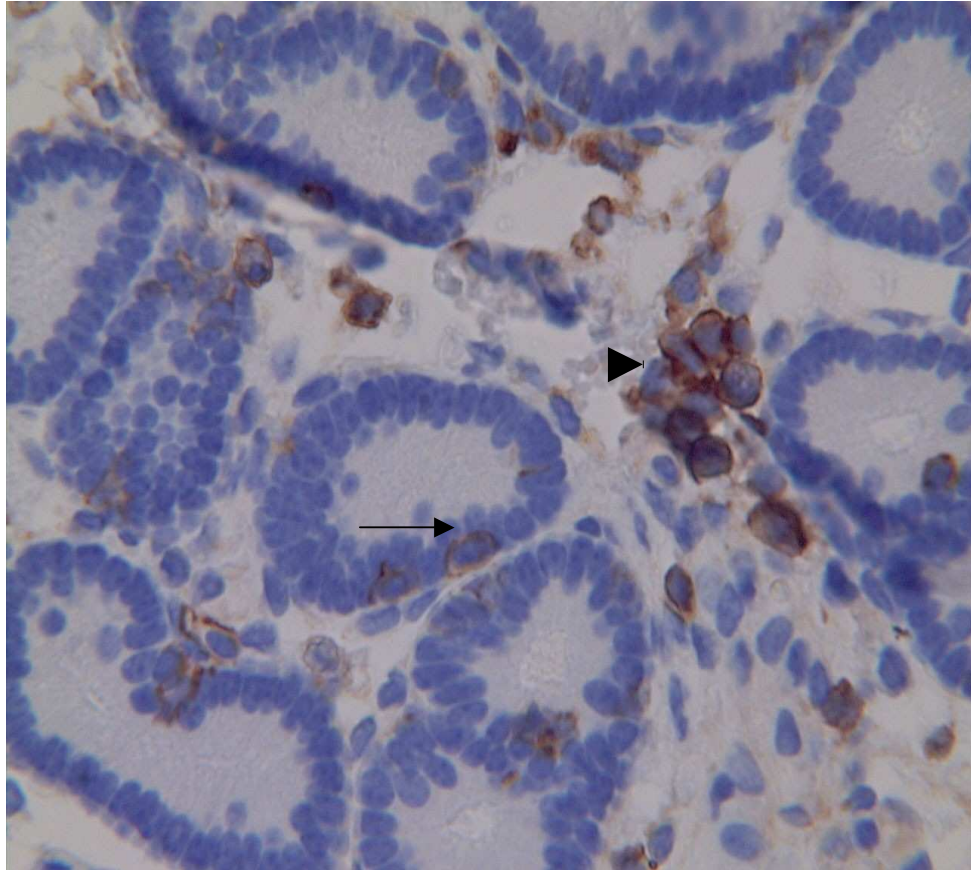


Figure 2a and b: Immunolabelling for CD44 of the equine uterus. Uterine glands, x 100. Black arrow depicts CD44-positive staining of the cell membrane of a uterine gland epithelial cell. Black arrow heads indicate CD44-positive stain of the cell membrane of lymphocytes.

(b)





(c)

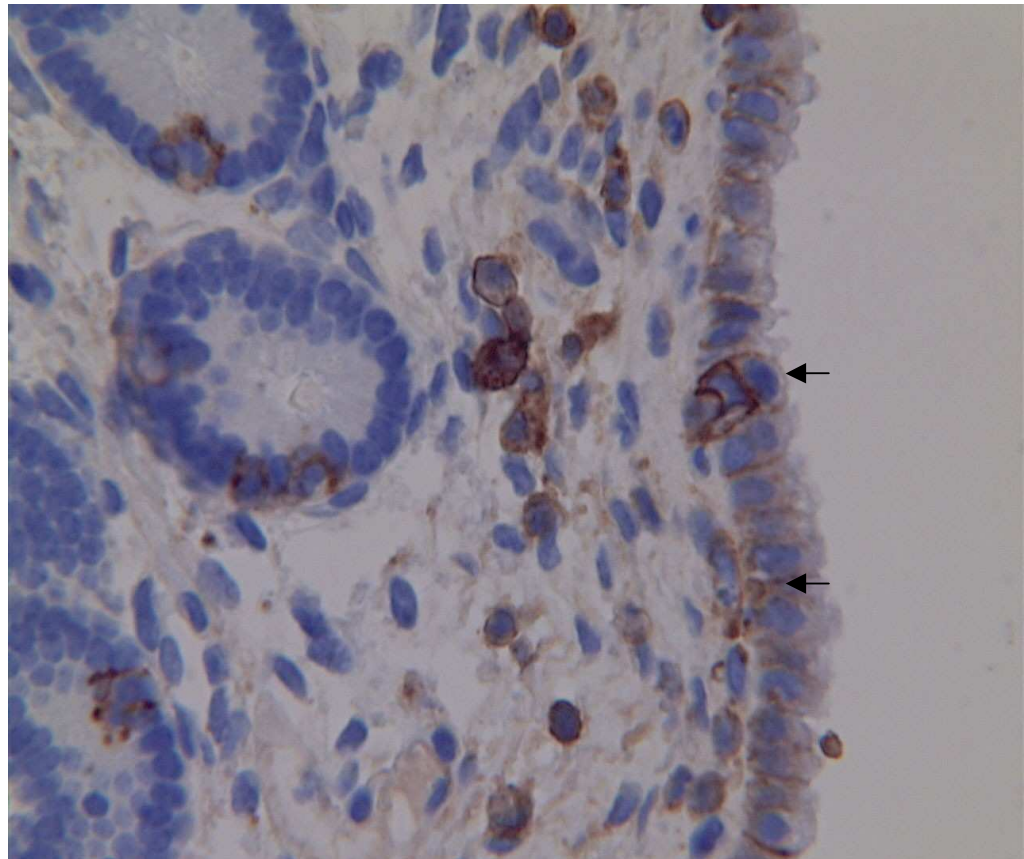


Figure 2c: Immunolabelling for CD44 of the equine uterus. Endometrium, x 100.  
Black arrows depict CD44-positive staining on the basolateral membranes of the  
endometrial epithelial cells.

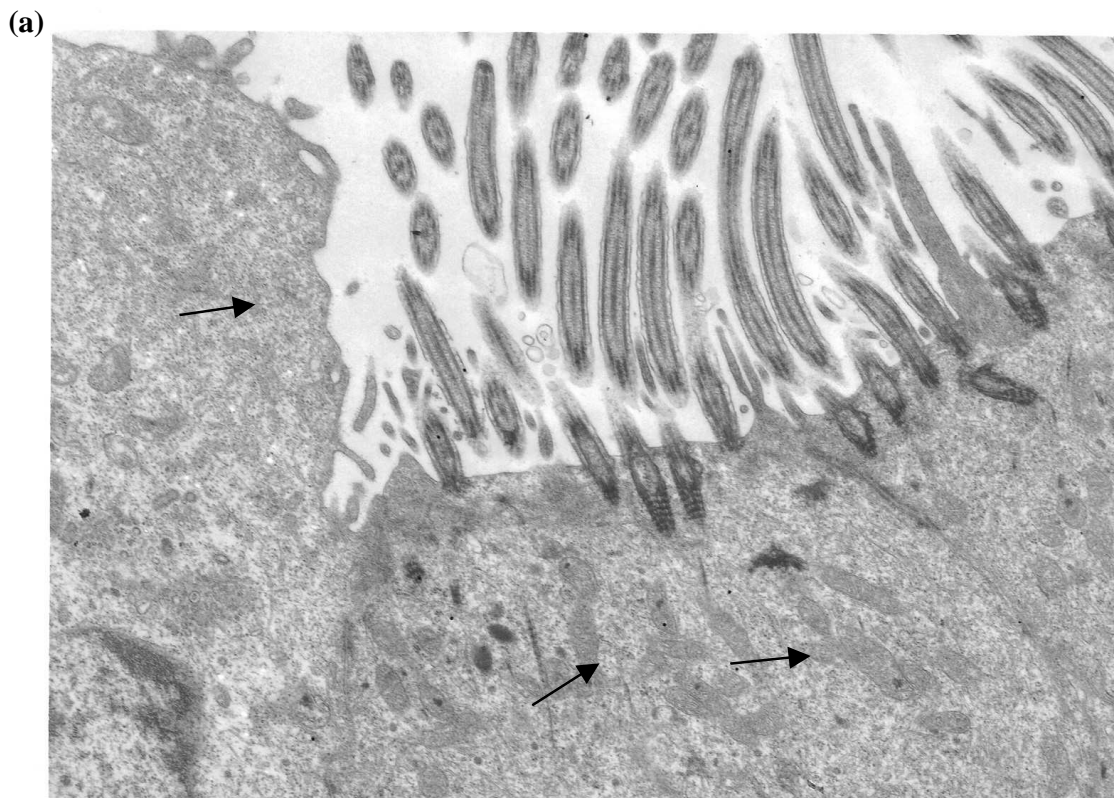
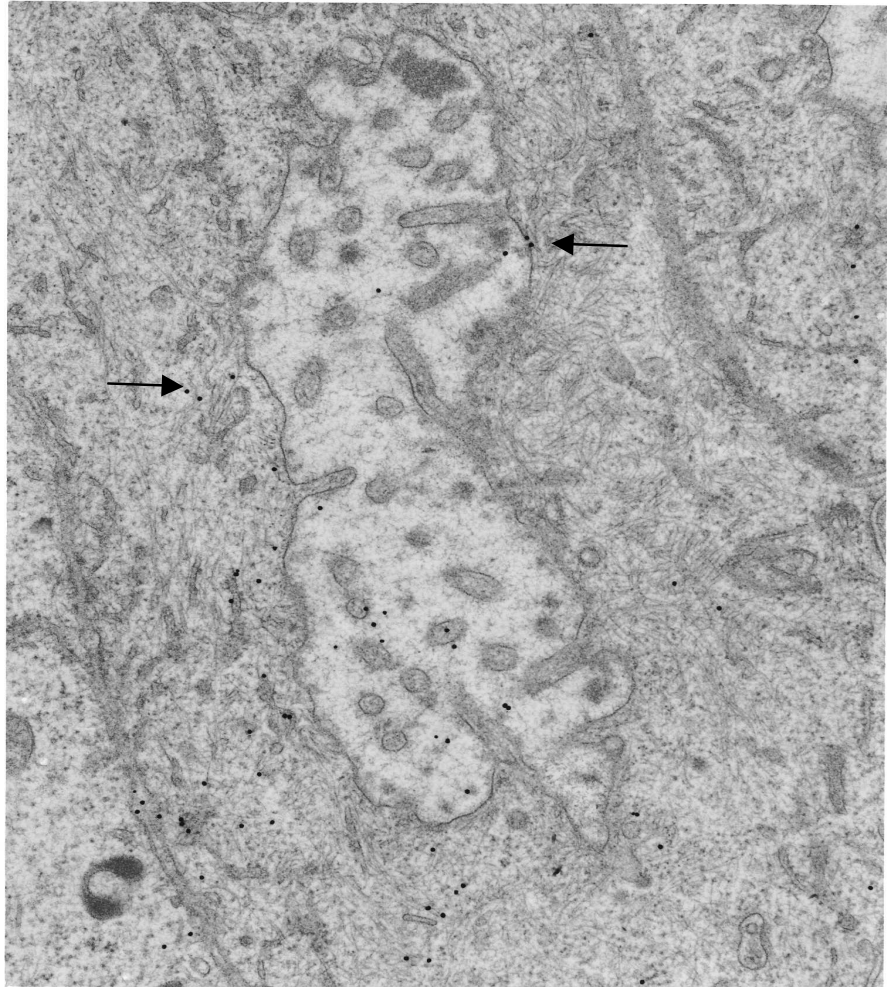


Figure 3: Immunoelectron Microscopy for CD44 of the equine oviduct. The colloid was identified in the cellular surfaces of ciliated cells, associated with the cilia and the extracellular matrices (a), as well as intracellularly (b). Arrows depict the presence of colloid.

(b)



**Table 1 Signalment of the mares used in the study: breed, age (years) and endometrial biopsy category.**

<b>Mare number</b>	<b>Breed*</b>	<b>Age (years)</b>	<b>Endometrial biopsy category</b>
1	AQH	4	I
2	AQH	5	I
3	TWH	8	I
4	THB	11	I
5	THB	14	II
6	AQH	16	II

\*AQH- American Quarter Horse, TWH- Tennessee walking horse and THB- Thoroughbred.

**Table 2 Expression of CD44 by Component Segments of the Mare Reproductive Tracts**

<b>Mare</b>	<b>Ovary</b>	<b>Infundibulum</b>	<b>Ampulla</b>	<b>Isthmus</b>	<b>Endometrial epithelium</b>	<b>Endometrial glands</b>	<b>Endometrial serosa</b>
1	Moderate	Strong	Moderate	Moderate	strong	mild	strong
2	mild	strong	moderate	mild	moderate	mild	strong
3	mild	strong	moderate	moderate	strong	mild	strong
4	moderate	strong	strong	moderate	moderate	mild	strong
5	mild	strong	moderate	moderate	strong	moderate	strong
6	mild	strong	strong	moderate	strong	moderate	strong